

## Endobronchial Schwannoma : A Rare Diagnosis

Rahul Gupta, Pritpal Singh\*

### Abstract

Schwannomas are uncommon and often benign neoplasms developing from the nerve sheath of the peripheral nervous system. Thoracic schwannomas most often appear in the posterior mediastinum and costovertebral angle. Pulmonary schwannomas are exceedingly rare and can present a diagnostic challenge. Here we report a case of a solitary right-sided endobronchial schwannoma presenting with progressive respiratory symptoms and discuss the clinical features, histopathological manifestations and diagnostic considerations of this rare tumor.

### Key Words

Schwannomas, Endobronchial , Neurofibromatosis

### Introduction

Endobronchial schwannomas are rare and often benign neoplasms that develop from the nerve sheath of the peripheral nervous system (1). The incidence of primary neurogenic tumors of the lung has been estimated to be 0 to 2 % of all lung tumors (2). These tumors originate from Schwann cells (3) and are predominantly (75%) are associated with Neurofibromatosis of Von Recklinghausen disease (4). This can present either as a solitary benign neoplasm or a malignant form (rare) in the lung.

### Case Report

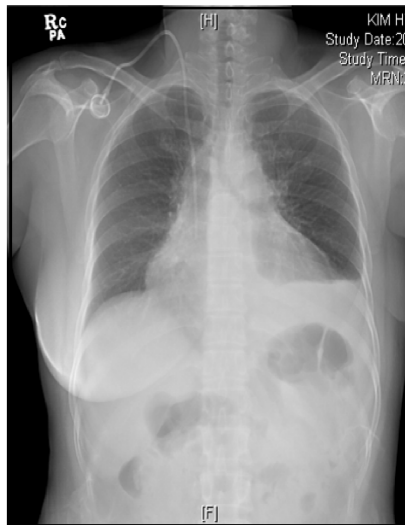
A 51 years old female presented to us with chief complaints of cough with expectoration and dyspnoea of 2 months duration. In 2010, she was diagnosed with Thyroid carcinoma and underwent thyroidectomy and Radiotherapy. There is no past history of Hypertension, Diabetes, Pulmonary Tuberculosis or Bronchial Asthma. Patient is reformed smoker and non alcoholic. General physical examination was normal. Chest examination

showed symmetric chest wall expansion, harsh vesicular breath sounds without crackles, decreased breath sounds in left lower lung fields. Other systemic examination was normal. Lab investigations were within normal limits. Chest X ray showed moderate amount of pleural effusion in left hemithorax and cardiomegaly raising the suspicion of pericardial effusion. CT chest shows endobronchial nodule in carina and right main bronchus. A Flexible Bronchoscopy was performed and revealed a large, white, smooth, well-vascularised tumor obstructing 50% distal trachea and right main bronchus. Provisional diagnosis of Endobronchial metastasis with thyroid cancer was made keeping differential diagnoses of the other conditions with central airway obstruction also. The mass was mechanically removed and histopathology showed bland looking spindle cells with some lymphocytes infiltration and collagen fibres in intercellular spaces. Uniform and intense immunostaining for S-100 protein

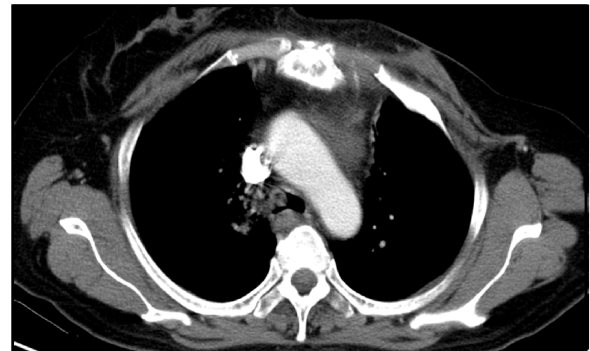---

From the Department of Chest Disease & Medicine\*, Govt Medical College Jammu J&K India

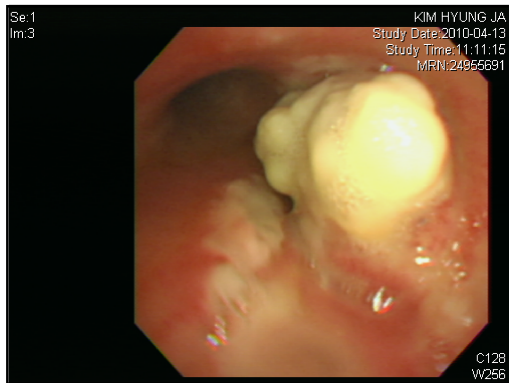
Correspondence to : Dr Rahul Gupta Lecturer, Chest Disease Department, Govt Medical College Jammu J&K India



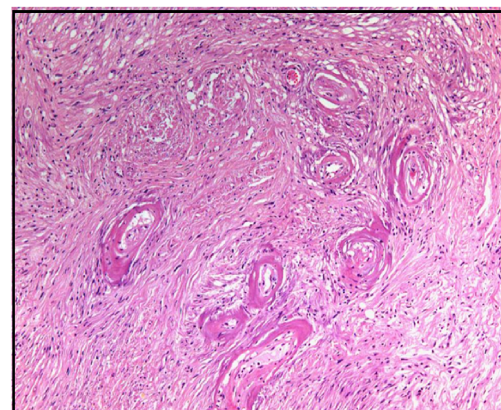
**Fig. 1** Showing Pleural Effusion in left Hemithorax



**Fig. 2** Showing Endobronchial Nodule in Carina and Right Main Bronchus



**Fig. 3** Bronchoscopy view Showing a large, White, Smooth, Well- Vascularised Tumor in Right Main Bronchus



**Fig. 4** Histopathology Showing Bland looking Spindle Cell & Collagen Fibers in Intercellular Spaces

confirmed the diagnosis of endobronchial schwannoma.

### Discussion

Schwannomas or Neurilemmomas are benign nerve-sheath tumours which arise wherever there are medullated nerves, spinal nerve roots being the most common primary location (5). Primary Neurogenic tumors are mostly seen in association with Neurofibromatosis, isolated Schwannomas are rare (6). Benign endobronchial tumors themselves are uncommon, and of these, endobronchial schwannoma is a rare entity. It is estimated that they may make up only 0.2% of all intrapulmonary neoplasms (1,7). Neurogenic tumors are rare and can manifest at any age with most occurring in

young adulthood, after age 20 years (8). Schwannomas can occur in all regions of the tracheobronchial tree, with intraluminal and/or extraluminal extensions. They can occur centrally in the airways as well as peripherally in the lung parenchyma (9). Schwannoma of the lung is a benign neoplasm that is usually detected during routine X-ray examination, most patients being asymptomatic. The clinical presentation of endobronchial schwannoma varies and depends on the tumor location, size, and degree of bronchial obstruction. Symptoms include dry or productive cough, fever, hemoptysis, dyspnea, and post obstructive pneumonia, and any one of these can be the first sign of bronchial schwannoma (10). Radiologically, the tumours appear as round, ovoid or lobulated, homogenous masses with a sharp outline, and occasionally with spotty calcification. The

appearance of schwannoma has been described as a well-circumscribed, homogeneous mass of soft tissue density whereas inhomogeneity would be suggestive of malignancy (11). At bronchoscopy, the lesion may be seen as a polypoid mass bulging into the bronchial lumen or raising the bronchial mucosa, which may be then ulcerated. As clinical and radiological impression vary and CT imaging cannot be used to differentiate the nature of tumor, biopsy is required in most cases. In the diagnostic process, the identification of the characteristics of schwannoma, including typical Antoni A formation and Verocay bodies in hematoxylin and eosin stains and S100 positivity aids in confirming the correct diagnosis of schwannoma (12). Antoni type A (cellular pattern) is formed of compactly arranged spindle cells with elongated nuclei disposed in parallel rows, creating a pattern of palisades (11). Clinically, the differential diagnosis of pulmonary schwannoma is that of a pulmonary round focus. Histologically, spindle cell tumours must be ruled out, leiomyoma, fibroma and sclerosing haemangioma being the usual types in this location (11). Finally, the encapsulation of these tumours usually permits complete surgical enucleation, although, sometimes, resection of adjacent lung tissue may be indicated. In patients with intrabronchial tumours, the mass may be removed endoscopically (7).

### Conclusion

Although endobronchial schwannoma is rare, awareness of the possibility of schwannoma involving the bronchus might be helpful in making a correct diagnosis. After diagnosing the tumor, proper management based on each patient's clinical setting is required. Our study revealed successful results following bronchoscopic removal of endobronchial schwannomas.

### References

1. Nasiri H, Zeki AA, Timothy. A rare diagnosis: Endobronchial schwannoma. *Journal Res Diseases* 2010; Available at: [www.physicianpractice.com](http://www.physicianpractice.com)
2. Roviato, Montorsi M, Varoli F, Buda R, Cecchetto A. Primary pulmonary tumors of neurogenic origin. *Thorax* 1983; 38:942-45
3. Smith LH. Thoracic neurofibromas. *Ann Thorac Surg* 1977; 23:586-92
4. Muhrr KH, Fischer HP. Primary pulmonary neurilemmoma. *Thorac Cardiovasc Surg* 1983; 31:313-16
5. Harkin JC, Reed RJ. Tumors of the peripheral nervous system. *Am J Pathol* 1969; 55(2):191-202
6. Walker MD. - Brain and peripheral nervous system tumors. /n: Cancer medicine. J.F. Holland, E. Frei III eds. Lea & Febiger, Philadelphia, 1973. pp. 1385-1407.
7. Bartley TD, Arian VM. - Intrapulmonary neurogenic tumors. *Thorac Cardiovasc Surg*, 1965, 50, 114-123.
8. Righini CA, Lequeux T, Laverriere MH, Reyt E. Primary tracheal schwannoma: one case report and a literature review. *Eur Arch Otorhinolaryngol* 2005; 262:157-160
9. Kasahara K, Fukuoka K, Konishi M, et al. Two cases of endobronchial neurilemmoma and review of the literature in Japan. *Intern Med* 2003; 42:1215-18.
10. Oxner CR, Shinnors MJ, Godin DA, et al. Obstructing tracheobronchial schwannoma. *J La State Med Soc* 2005; 157: 159-61.
11. Bosch X, Ramfrez J, Font J, Bomb JA, et al. Primary intrapulmonary benign schwannoma. A case with ultrastructural and immunohistochemical confirmation. *Eur Resplr J* 1990, 3, 234-237
12. Yoon Yang Jung, Min Eui Hong, Joungho Han et al. Bronchial Schwannomas: Clinicopathologic Analysis of 7 Cases. *Korean J Pathology* 2013; 47: 326-331